Hughston Health Alert

6262 Hamilton Road P.O. Box 9517 Columbus GA 31995-3199

VOLUME 2, NUMBER 4 | *For a Healthier Lifestyle* | FALL,1990

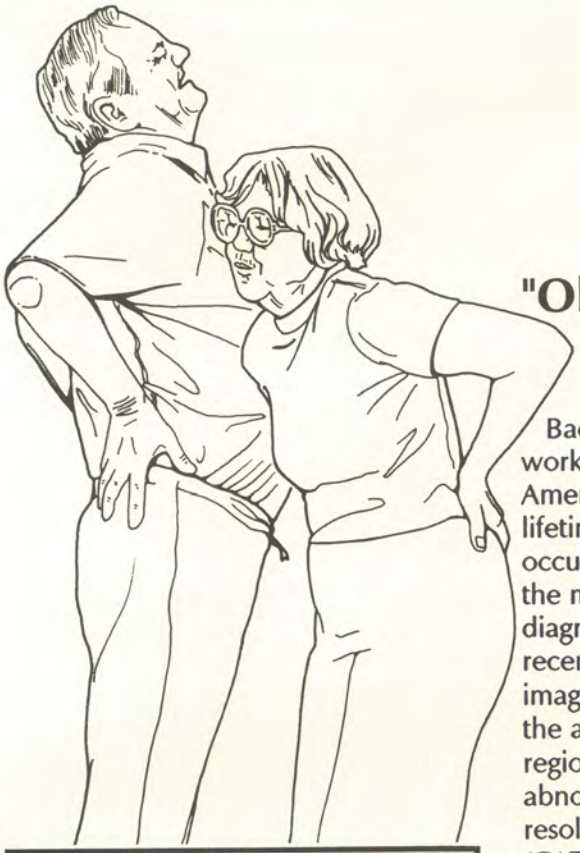

LOW-BACK PAIN
Current Methods of Evaluation & Treatment

Inside This Issue:

- Sacroiliac Dysfunction
- Spondylolisthesis
- Spinal Stenosis
- Spinal Imaging
- Stretch, Walk for Back Fitness
- The Lumbosacral Corset
- Dorsal Column Stimulator
- When is Surgery Necessary to Relieve Low Back Pain

"Oh, My Aching Back"

Back pain, the leading cause of lost work time, afflicts seven out of ten Americans at some point during their lifetime. In spite of its high rate of occurrence, back pain remains one of the most difficult conditions to diagnose and treat effectively. In recent years, however, advanced imaging techniques have improved the ability to evaluate the lower back region. Intricate anatomy and subtle abnormalities can be seen with high resolution computerized tomography (CAT) scanning, and magnetic resonance imaging (MRI) uses magnetism to visualize the normal anatomy and disorders of the lumbar spine in even greater detail. Despite these new imaging techniques, a full evaluation of low-back problems should rely heavily on a careful clinical history and a detailed physical examination. This issue is dedicated to current methods of evaluating and treating low-back pain.

Thomas N. Bernard, Jr., M.D.
Columbus, Georgia

One Symptom, Many Causes

Low-back pain can be treated effectively only if its cause is known. Yet that cause must first be identified from a number of possible sources. Some sources of back pain that often come to mind are a slipped disk, herniated disk, and ruptured disk (all synonymous terms) as well as pinched nerves and muscle strains.

Back pain, however, has many other causes, the most common of which is injury to the posterior facet joints, the small joints that connect one vertebra to another (see front cover). These joints support about 25% of the weight of the trunk in the standing position (the lumbar disks support the remaining 75%). The posterior facet joints, like other joints, can be injured by trauma, inflammatory diseases such as arthritis, or overuse. When these joints become irritated, patients often feel acute pain in the back, which prevents them from standing erect, and have associated muscle spasm and pain in the buttocks and possibly the leg. Often, this condition mimics a ruptured disk or pinched nerve.

The second most common cause of low-back pain is sacroiliac (SI) joint syndrome. The sacroiliac joint (Fig. 1), like the posterior facet joint, is subject to traumatic and inflammatory conditions. SI joint syndrome can cause localized pain in the back and buttocks region as well as referred pain in the leg.

Both the posterior facet joint and sacroiliac joint syndromes are treated initially with joint mobilization, joint manipulation, or joint injection. A well-directed exercise program can prevent a recurrence of symptoms. Occasionally, a short course of an anti-inflammatory medication may be used in conjunction with these treatment methods.

The lumbar disk, another common source of low-back pain, need not be ruptured or herniated (protruding through an abnormal opening) to be a source of pain. The patient may experience a dull, ill-defined low-back pain that is usually aggravated by activity and relieved by bed rest. Computerized tomography, magnetic resonance imaging, and lumbar diskography are often needed to confirm a diagnosis. Once recognized, contained diskogenic or disk-type pain is treated initially with an exercise program to strengthen the supporting back muscles. Occasionally, an epidural cortisone injection may help to break the pain cycle. If conservative measures fail, removal of the painful disk and a fusion of the area may give lasting relief. When a fusion is performed, bone graft material is placed over two adjacent vertebrae in order to biologically unite these structures (see back cover).

When a lumbar disk herniates, it usually comes in contact with a nerve root and causes low-back pain that radiates into the leg. This pain may be accompanied by numbness, tingling, or weakness in the leg. For the majority of patients, symptoms usually improve with time and modification of activity. However, if symptoms persist, surgery may be necessary. The patient's activity level, occupation, and the location of the disk herniation determine whether only the disk herniation should be removed or whether a fusion is also required.

Patients should be aware of certain danger signs associated with low-back pain. Increasing numbness, tingling, weakness, or loss of control of bowel or bladder function require urgent medical attention. In addition, internal conditions in the gastrointestinal tract, kidneys, or pelvic organs can mimic various types of back pain. Generally, patients experiencing low-back pain should first contact a physician for proper evaluation and referral to a specialist when appropriate.

Thomas N. Bernard, Jr., M.D.
Columbus, Georgia

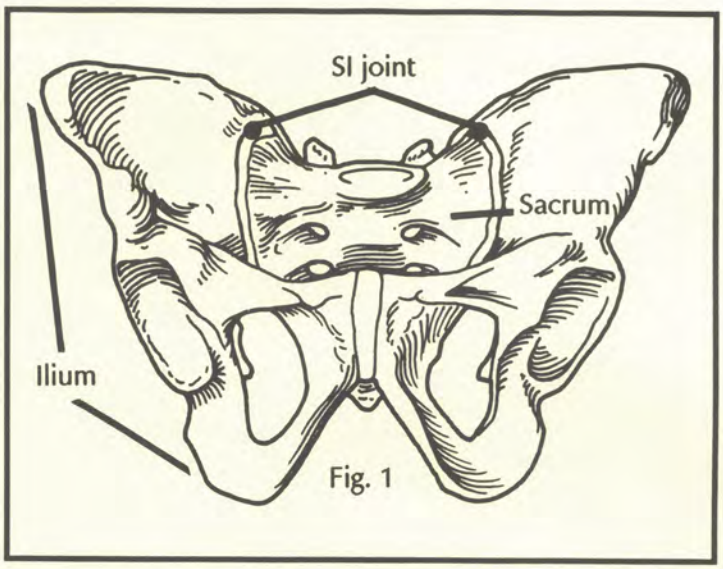

Fig. 1

Sacroiliac Dysfunction

Do you have an aching, stiff back when you wake up in the morning? Is it difficult to stand up after sitting because your back feels stiff? When your back hurts, does it feel better after you stand and move around? If the answer to any of these questions is "Yes," you may have a sacroiliac joint dysfunction.

The sacroiliac (SI) joint is an irregularly shaped joint that connects the ilium (pelvic bone) with the sacrum (tailbone) (Fig. 1). This joint has relatively little range of movement, especially when compared to the combined range of motion found in the joints of the spine and the very flexible hip joint. The SI joint cushions shock that is translated horizontally across the thin iliac bone. As a result of this protective roll, the joint is subject to many stresses that may result in a sprain.

A common cause of injury to the SI joint is trauma that results from a fall in which one lands on the buttocks. Sometimes the fall results in a small fracture in the tailbone. Pain that persists after the fracture has healed emanates from the SI joint rather than from the fracture and should receive further medical attention. Other causes of trauma sufficient to injure this joint include lifting and motor vehicle accidents.

Occasionally there is no known injury. Pain emanates from the SI joint as a result of prolonged stress applied to the joint while sitting for extended periods, as during long airplane flights and automobile trips. After a trip, the joint is inflamed and the back feels tired. The joint is actually as injured and inflamed as if a fall had occurred. Subsequently, the body forms scar tissue that restores stability to the area by tightly knitting together torn or stretched tissue. If full range of motion is not achieved during this healing process, the joint becomes stiff and dysfunctional.

The pain and irritation from a dysfunctional SI joint may be intolerable. When a movement is made that requires movement in the joint, an intense muscle spasm can

result, as when one's back "goes out" on turning to answer a phone or pick up a pencil.

Treatment begins with an examination by a physician to rule out disorders that require surgery, such as a ruptured disk or a pinched nerve. If such a disorder is not found, a physical therapist will evaluate joint range of motion. If the joint is stiff, an appropriate stretching technique is used to restore normal range of motion. After motion is restored, strengthening exercises are prescribed to rehabilitate weakened back muscles.

The explanation that back pain is "just arthritis" or "normal for one's age" should not be readily accepted. Most back problems are related to weak muscles or joint dysfunctions and can be treated effectively by a trained physical therapist.

Herb Silver, P.T.
Columbus, Georgia

Spondylolisthesis

Back pain in adolescent athletes

Back pain in teenage athletes, especially weightlifters, suggests the possibility of spondylolisthesis, a condition that occurs in an estimated 5% of the population. Although the condition is not uncommon, few patients develop symptoms that require treatment.

What is spondylolisthesis?

The functional unit of the spine consists of the vertebral body, intervertebral disk, and neural arch (Fig. 2a). The neural arch joins the vertebral body similar to the way in which the walls of a house join its foundation. Discontinuity at the point of juncture (pars interarticularis) results in a condition called spondylolysis (spine separation)(Fig. 2b). If the vertebral body slips forward on its neighboring vertebra, the condition is called spondylolisthesis (Fig. 2c).

What causes the condition?

A few people are born with a deficient neural arch. However, in most cases the problem develops before adolescence and is usually caused by repetitive injury to the neural arch at its weakest point where it joins the vertebral body. Hyperextension of the lower back (excessive back bends such as those done by football linemen and gymnasts) is believed to cause the condition. It is not uncommon to see one or more "cracks" in the lower back of a gymnast.

What are the symptoms?

Back pain, sometimes accompanied by pain down the back of the thighs, is common. Bending backward usually worsens the pain. A lineman may experience pain when rising from a set and during blocking with the spine in a hyperextended position. Gymnasts may experience pain during routines that require arching the spine backward. Occasional numbness or weakness may occur in the foot or leg because of irritation or compression of the nerves that are in close proximity to the loose neural arch.

What can be done?

Usually, simple remedies such as rest, temporarily discontinuing the painful activity, and mild analgesics are effective. Physical therapy helps teach patients to self-stabilize spondylolisthesis through lower body control and specific exercises. In some cases, bracing may be necessary to encourage healing of an acute injury. In young patients with progressive spondylolisthesis, surgical stabilization may be required (see back cover). Patients requiring spinal fusion (bonding of the movable segments of the spine) can resume most activities, including contact sports in some cases, after the fusion has healed satisfactorily.

Richard J. Nasca, M.D.
Columbus, Georgia

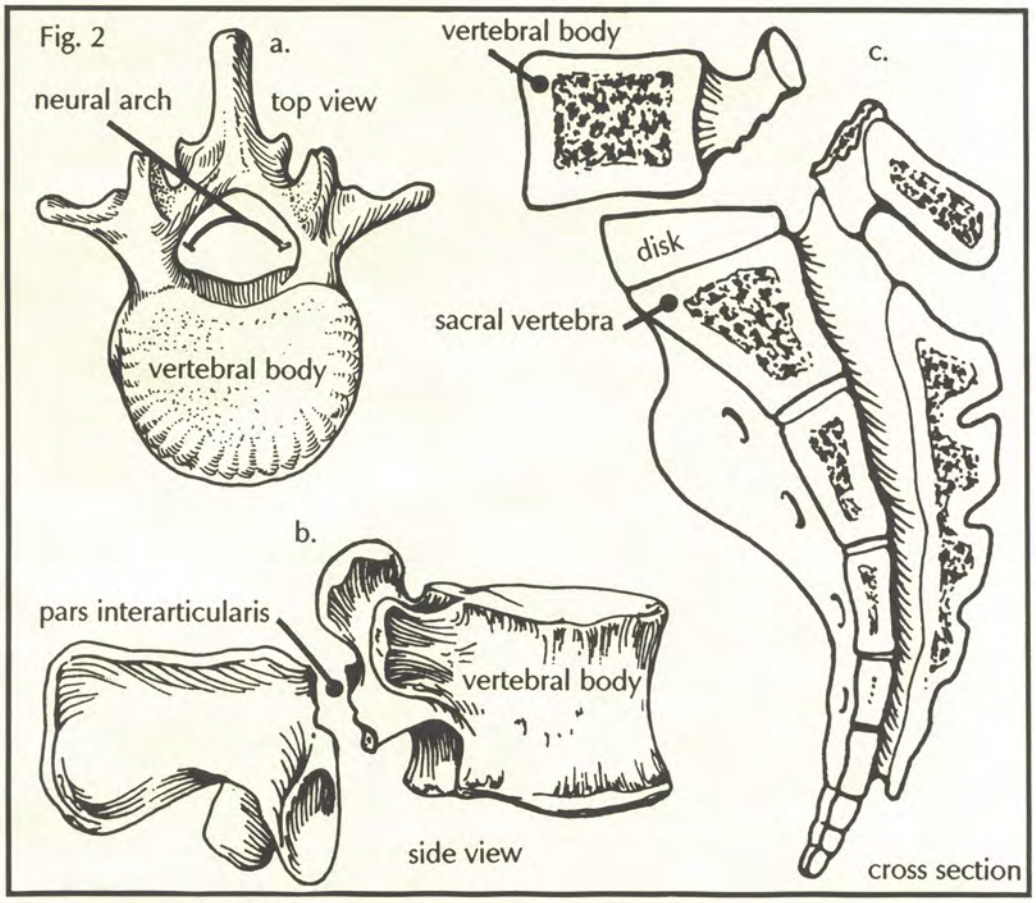

THE AGELESS ATHLETE

Spinal Stenosis

Spinal stenosis, a narrowing of the spinal canal or nerve root canals, is a common cause of back pain in older people. In most cases, the condition results from degeneration of the disks and small joints of the back (facet joints). As the disks degenerate, the space between the bones narrows and the diameter of the spinal canal is reduced (Fig. 1), which crowds the nerves and spinal cord elements (Fig. 2).

What are the symptoms?

Patients usually complain of leg pain that is intensified by walking uphill, standing for long periods of time, and hyperextending the back (bending backward). Patients are awakened at night with leg pain and may complain of "pins and needles" sensations in their legs. Often, symptoms are similar to those associated with poor circulation, a condition that can co-exist with spinal stenosis. Patients with spinal stenosis can usually ride an exercise bicycle comfortably, while those with vascular problems in their legs cannot. Occasionally, spinal stenosis may cause difficulty with bowel or bladder control, retention of urine or frequent urination. Men with vascular insufficiency may become impotent.

What can be done?

Rest, a decrease in activities that cause the symptoms, strengthening exercises for the back and leg muscles, and anti-inflammatory medication are helpful. However, symptoms may persist in spite of these simple measures. An injection of cortisone (epidural steroids) into the space around the nerves of the lower back may relieve the pain. The injections may be repeated safely every four to six weeks for a total of three to four injections. However, if symptoms persist or worsen after an injection, surgical decompression is usually necessary.

Surgical treatment

To provide more room for the spinal nerves and spinal cord, bone is removed from the posterior (back) of the spine. Bone spurs pushing on nerves are removed, and the facet joints may also require partial removal. Back instability that occurs as a result of either surgery or the disease process may require a spinal fusion in addition to the decompression. In a spinal fusion, bone is scraped and additional bone added so that the movable segments of the spine join together and no longer move (see back cover).

How well do patients function after surgery?

In a study of more than 100 patients with spinal stenosis, about 80% achieved a satisfactory result following surgery. Most patients report improvement in their ability to walk and perform normal activities and hobbies. Occasionally, there is so much damage to the nerves that decompression does not reduce the symptoms. For these patients, pain control techniques such as the use of an epidural spinal stimulator may be helpful (see Research, p. 7). There are a few medications that can alleviate some symptoms, but no medication can reverse the disease process.

Patients undergoing surgery are usually hospitalized for three to five days and are allowed to resume normal activities, with the exception of stressful sports activities and repetitive lifting, as soon as they leave the hospital. Postoperative rehabilitation includes walking, riding an exercise bicycle, and swimming. Patients are also instructed in stretching exercises and exercises to strengthen the muscles in the back, pelvis, and legs.

Richard J. Nasca, M.D.
Columbus, Georgia

Fig. 1

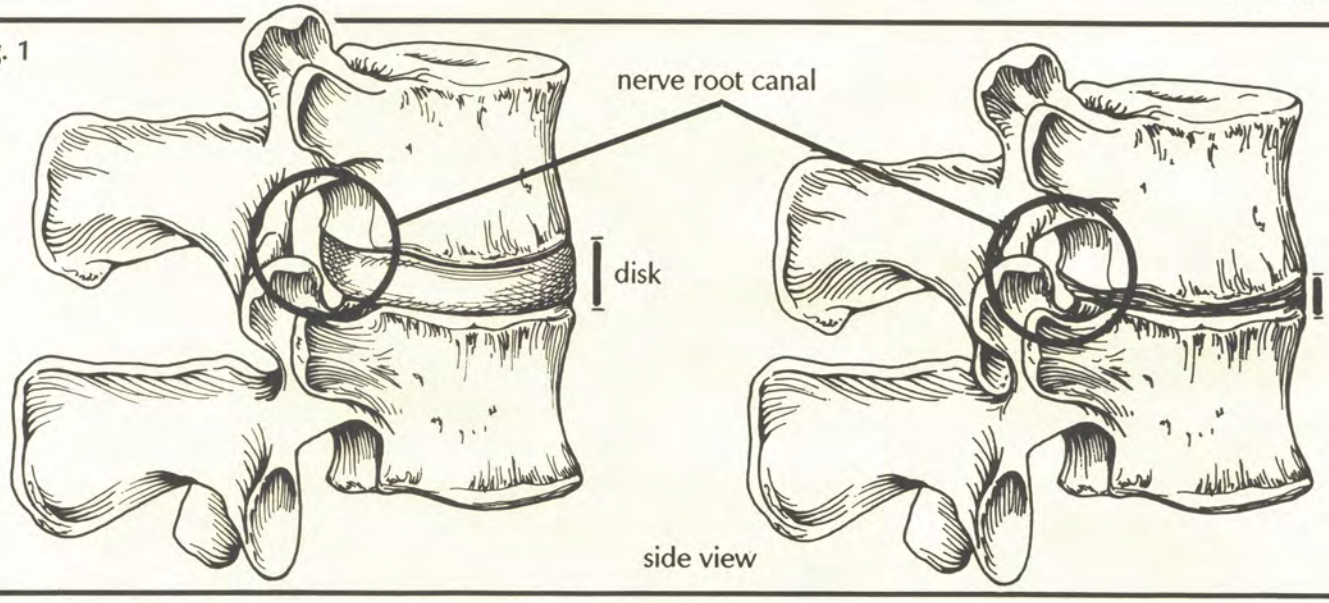

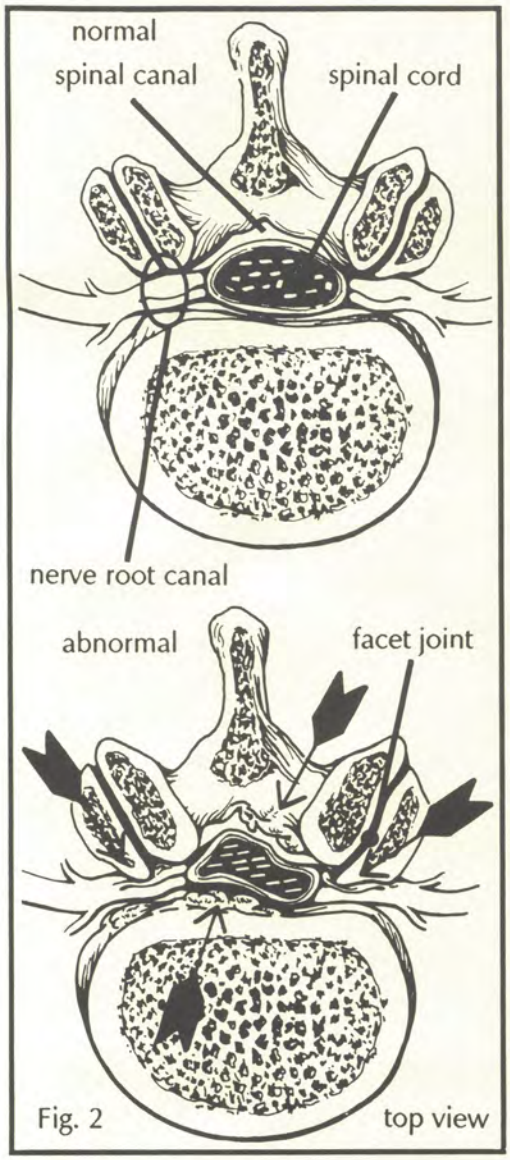

Fig. 2

Spinal Imaging

Evolving methods for evaluating back pain

Gone are the days when significant spine disorders were evaluated with only a set of plain x-ray films. A variety of methods of viewing the spine nonoperatively are now available and continue to be developed. Although most viewing methods involve some form of radiation to produce an image, or picture, some newer methods, such as magnetic resonance imaging (MRI), use no radiation at all. Although many of these newer, more sophisticated studies are still performed in hospital radiology departments, the terms "radiologic studies" and "x-ray studies" are gradually being replaced by the term "spinal imaging."

To fully delineate a particular problem, the spine surgeon, in conjunction with the radiologist, usually requires a combination of imaging studies performed in a step-wise, logical sequence. The surgeon must determine which combination of studies gives the information needed without subjecting the patient to needless tests that would add unnecessary expense and exposure to radiation. Data gained from the various studies may overlap, but each study often contributes a unique piece of information not available from any other test. With this information, the surgeon is able to make a more specific diagnosis and thus formulate the most effective treatment plan for each patient. Any patient with a serious spinal disorder may expect to undergo more than one of the following commonly used spinal imaging tests.

X-ray

Regular x-ray views, routinely taken in the physician's office during an initial visit, are used as a screening procedure to look for fractures, arthritic changes, curvature of the spine, and malalignment or bone destruction caused by an infection or a tumor. Cartilage, disk, and muscle cannot be studied using this method.

Bone scan

A bone scan is done with a radiation detector after a radionuclide is injected into the bloodstream and is subsequently absorbed by the bones. This study allows examination of the entire skeletal system and can detect the changes of early arthritis as well as bone fractures and early infections that cannot yet be seen on regular x-rays. Although the idea of an injection of radioactive material may cause concern, the total exposure is no more than that of a routine set of plain x-rays.

CAT scan

Computerized axial tomography (a CAT scan) is performed with a sophisticated x-ray unit that uses computer technology to produce pictures of the body in cross sections, a thin slice at a time. Each slice can be pulled out and studied separately, as a slice of bread is pulled from a loaf. Using this technique, disks and soft tissues can be studied in great detail. An average CAT scan takes approximately 45 minutes to perform.

Myelogram

The myelogram is done using conventional x-rays and a fluoroscope (a device used for examining deep structures) with the addition of a contrast material, or dye, that is injected into the spinal canal. By outlining the nerve roots and disks, the dye helps to diagnose disk herniations and nerve root abnormalities.

Diskogram

The diskogram is done with routine x-rays and fluoroscopy after a contrast material, or dye, is injected directly into the disk. The examination is used to determine if the disk is degenerated or herniated and if that disk is responsible for the patient's pain.

MRI

Magnetic resonance imaging (MRI) is the most sophisticated imaging technique available and uses magnetism rather than x-rays to study the spine from any angle and in any plane. This method allows the spinal cord, bone marrow, disks, and soft tissues to be studied in great detail. Anyone with implanted metallic objects such as vascular clips, pacemakers, and welding fragments may not be a candidate for this test.

Sandra McCann, M.D.
Fred Flandry, M.D.
Columbus, Georgia

TRAINING FOR A BETTER LIFESTYLE

Stretch, Walk for Back Fitness

The most effective exercise program for maintaining a healthy back includes both stretching for flexibility and walking for general fitness. The following exercises can be used to properly condition the back.

Extension exercises improve low-back flexibility. Extension can be achieved with the prone-on-elbows exercise and the standing extension exercise.

Prone-on-elbows (Fig. 1a): Lie on the stomach and prop up on the elbows for a count of 10. Bring the arms out in front and lie comfortably to relax the lower back, middle back, neck, and shoulders. Repeat this exercise 10 times and progress to 30 repetitions, twice a day.

Standing extension (Fig. 1b): Stand with both hands placed on the lower back at the waist. Then, without overextending, lean back to a comfortable position, keeping the chin tucked in toward the chest. Hold for 5 counts and return to a relaxed position. This exercise may be repeated often during the day.

Keep the hamstrings flexible. These muscles are attached in the lower back and extend down the back of the leg to the knee. Tight hamstrings can cause nerve irritation and muscle spasms.

Supine hamstring stretch (Fig. 1c): Lie on the back with both legs down. Raise one leg and bend it at the knee. Place both hands behind the knee and straighten the leg. Keeping the knee as straight as possible, hold a comfortable stretch for 10 seconds. Relax and repeat with the opposite leg. Begin with 10 repetitions, twice a day. As the exercise becomes easier, increase gradually to 30 repetitions, twice a day.

Walking is good for low-back pain, weight loss, and general fitness. Too much weight strains the back muscles and can lead to a decrease in strength and endurance.

Walking program: Walk on a level surface for approximately 1/4 to 1/2 mile and increase gradually to approximately two miles, once a day.

If an exercise causes pain, it should be discontinued until a physician is consulted.

Barney Poole, M.Ed., P.T., A.T., C.
Columbus, Georgia

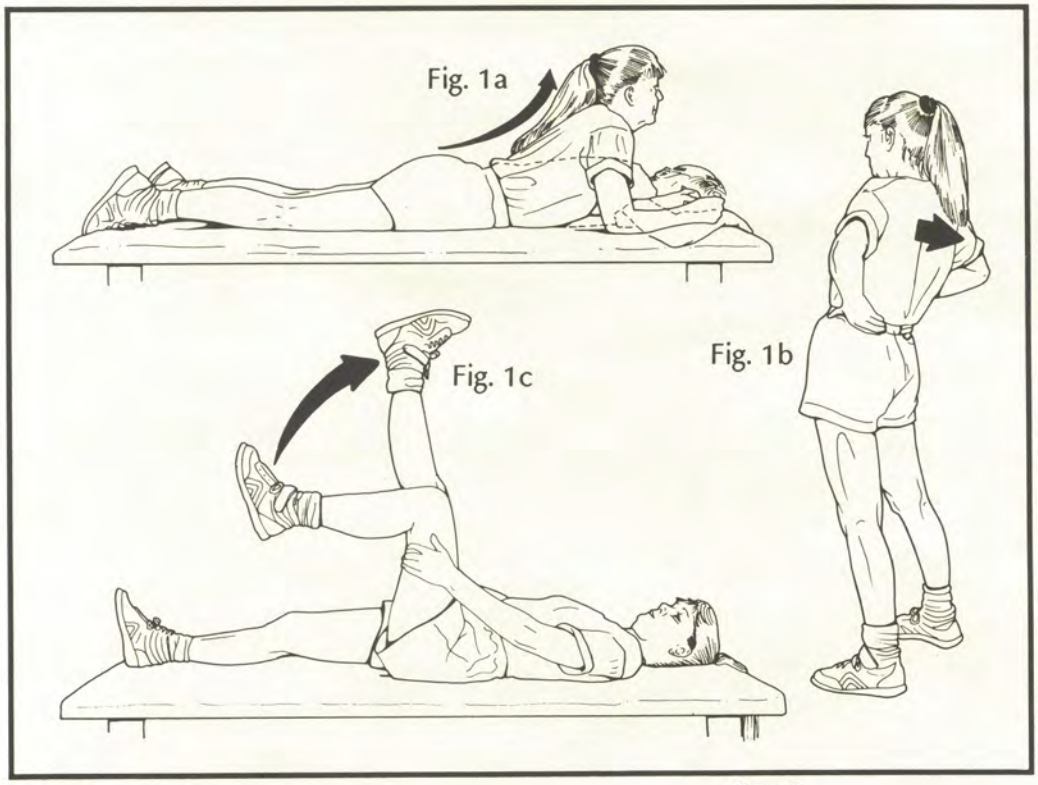

EQUIPMENT REVIEW

The Lumbosacral Corset

The lumbosacral (LS) corset is prescribed by physicians more than any other type of back support for the relief of low-back pain. Worn by both men and women, the many styles and sizes of LS corsets are designed to provide trunk support, motion control, and spinal realignment. Although much of the effectiveness of any corset comes from its abdominal support, the LS corset provides the added option of using steel stays that are molded to the patient's body and inserted into the back panel. These stays provide more rigid support when needed.

The LS corset is used primarily to relieve strain in the lumbar region of the spine, or lower back. This strain generally occurs as a result of sporting activities, improper lifting of heavy weights, and jobs such as truck driving that place prolonged stress on the back muscles.

A complete understanding of the patient's back problem is essential to determine which type of LS corset to use. The physician must first diagnose the disorder and then decide if a corset or brace would augment the treatment plan. The corset alone cannot treat or cure any condition; its purpose is to protect the back temporarily. The amount of time it must be worn is gradually reduced. The corset is not worn full time unless

the patient's disorder is particularly severe, as in the case of osteoporosis, lumbar disk degeneration, low-degree scoliosis, and patients who need support following surgery. An LS corset should be worn only when prescribed by a physician and it should be fabricated and custom-fitted by a certified orthotist or fitter. The patient's progress can then be monitored closely and adjustments made when necessary.

The prolonged use of any support without concurrent exercises or physical therapy can weaken spinal or back muscles. Patients sometimes tend to rely on the corset to hold the back erect, which causes their back muscles to grow weak from lack of use. Therefore, patients who are not required to wear the corset full time should follow an exercise program when not wearing the support.

Bruce O'Brien, C.P.O.
J. E. Hanger, Inc.
Columbus, Georgia

Photo by Yvonne Ehrhart

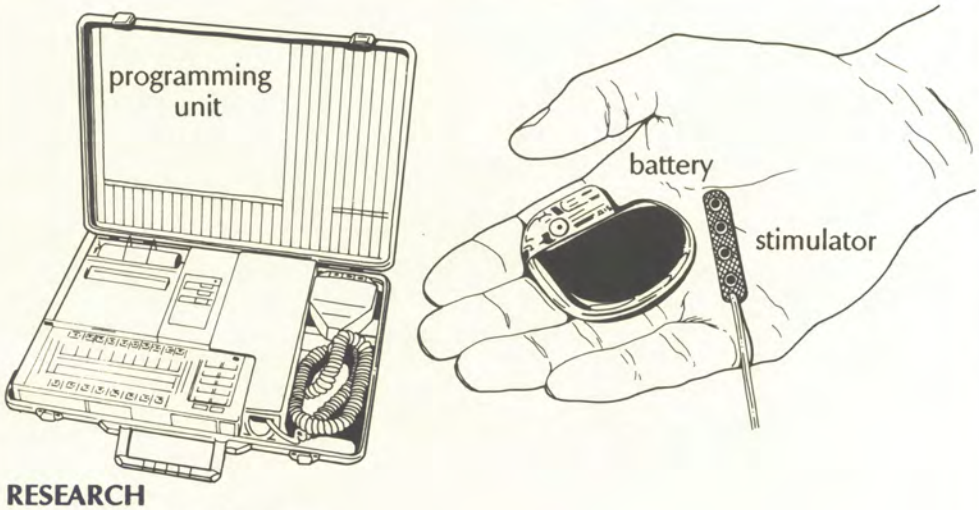

RESEARCH

Dorsal Column Stimulator

A surgically implanted stimulator is helping some sufferers of chronic low-back pain to lead more normal lives. The dorsal column stimulator, a device implanted either through the skin or in an open spine procedure, can control pain without the use of narcotics and their associated problems.

The dorsal column stimulator is used to manage chronic pain that results from arachnoiditis (inflammatory condition of the nerves), epidural fibrosis (scarring around nerve roots), or irreversibly damaged nerves. Under unusual circumstances, it may be used to control phantom limb pain following a lower extremity amputation or in patients with malignant disease affecting the spine. The dorsal column stimulator also has application in the cervical spine to control intractable neck and arm pain from similar problems that affect the lumbar spine.

The stimulator works on the "gate control theory of pain," the concept that the stimulation of the larger nerve fibers can inhibit smaller pain-carrying fibers, thus shutting the pathway, or "gate," through which pain signals reach the brain.

The dorsal column stimulator is powered by a battery or pulse generator enclosed in a water-tight, stainless steel case the size of a small cigarette lighter. The device can last as long as seven years and can generate unlimited types of stimulation. After implantation, the stimulator can be programmed or reprogrammed through the patient's skin without direct connection or discomfort. It can be placed in almost any segment of the spine (cervical, thoracic, or lumbar) to control pain. The average hospital stay for dorsal column stimulator implantation is five to seven days, three to five of which are spent learning about the stimulator and the fine adjustments programmed transdermally by the physician.

The dorsal column stimulator is not appropriate for everyone and is certainly not the answer for all back problems. However, the device may help patients who have constant pain that is not relieved by conventional treatments.

Bill Clemmons, PA-C
Columbus, Georgia

When is surgery necessary to relieve low back pain?

Do all sufferers of low-back pain need surgery? The answer is a resounding "No." Although back surgery has provided pain relief for millions of people since the first surgical removal of a ruptured disk in the 1930s, an operation is rarely indicated as the first treatment to consider. In fact, surgery is indicated only when proper criteria have been met and noninvasive measures have failed to relieve pain or disability. There are also many low-back conditions that do not respond favorably to surgery and are therefore treated by other means.

The only absolute indication for proceeding immediately with a back operation is the extremely rare occurrence of a cauda equina syndrome, a state of major paralysis of rapid onset that involves the nerves that control the bowel and the bladder. The condition is caused by a massive acute disk rupture or herniation.

Back surgery is not always successful, and the procedure is not without the risk of complications. Before a patient undergoes back surgery, the following questions should be discussed with the physician.

Is the timing of the surgery appropriate? A decision to operate should not be made too quickly. Mother Nature tries to heal and should be given a chance.

Has a reasonable attempt been made to relieve the condition by less drastic measures? Although it is unnecessary to exhaust all conservative measures before considering surgery, some should be tried.

Have the correct tests been done to establish a diagnosis, and do the imaging studies correlate with the clinical diagnosis? Imaging alone cannot always be relied on for a correct evaluation. Changes of degeneration within the disk, disk bulging, and arthritis are frequently seen as part of the "normal" aging process of the spine and are not necessarily the cause of the patient's pain, especially when the changes do not correlate with the doctor's clinical impression.

Are the anticipated benefits from surgery great enough to outweigh the potential risks? **No** doctor can operate on a back and make it normal. The goal of back surgery is not to eliminate the pain but to reduce it to a tolerable level. This is possible if patients stay physically fit and learn to live with their limitations.

Max E. Burr, M.D.
Columbus, Georgia

EDITORIAL BOARD

President & CEO
C. Dexter Jordan, Jr.
Editor
Fred Flandry, M.D.
Managing Editor
Judith B. Koren, M.A.
Copy Editor
Annette Ratliff, B.A.
Art Director
Carolyn M. Capers, M.S.M.I.
Circulation Coordinator
Faye K. Blanchard
Executive Director
Barry N. Morgan, C.P.A.

Karl Barkley, M.D.
Ken Bielak, M.D.
Robert Burger, M.D.
Kenny Howard, A.T.,C.
William E. Roundtree, M.D.
Robert Skerker, M.D.

Section Editors
Training For A Better Lifestyle
Barney Poole, M.Ed., P.T., A.T.,C.
Fitness
William C. Etchison, M.S.
The Ageless Athlete
John M. Henderson, D.O.
Research
Carlton G. Savory, M.D.
Nutrition
Jessie G. Wright, M.S., R.D., L.D.

HSMF CALENDAR

Red Cross Blood Drive
Thursday, Dec. 6th, 1990
1:00-4:30 pm
Contact: Linda (404) 576-2101

Chattahoochee Valley Arthritis Club
Nov. 15th - Holiday Social
Jan. 3rd - 7:00-9:00 pm
Contact: Vivian (404) 628-5915

The Hughston Health Alert is a quarterly publication of the Hughston Sports Medicine Foundation, Inc. The Foundation's mission is to help people of all ages attain the highest possible standards of musculoskeletal health, fitness, and athletic prowess. Information in the Hughston Health Alert reflects the experience and training of physicians at the Hughston Orthopaedic Clinic, P.C., of physical therapists and trainers at Rehabilitation Services of Columbus, Inc. and Committed Fitness Systems, of physicians who trained as residents and fellows under the auspices of the Hughston Sports Medicine Foundation, Inc., and of research scientists and other professional staff at the foundation. The information in the Hughston Health Alert is intended to supplement the advice of your personal physician, and should not be relied on for the treatment of an individual's specific medical problems.

Postmaster: Send address changes to Library, Hughston Sports Medicine Foundation, Inc., P.O. Box 9517, 6262 Hamilton Road, Columbus GA 31995-3199 USA. Telephone (404) 576-3322.

Copyright 1990, Hughston Sports Medicine Foundation, Inc.